

# Global Consensus Guidelines for the Injection of Diluted and Hyperdiluted Calcium Hydroxylapatite for Skin Tightening

KATE GOLDIE, MBChB,\* WOUTER PEETERS, MD,<sup>†</sup> MOHAMMED ALGHOUL, MD, FACS,<sup>‡</sup> KIMBERLY BUTTERWICK, MD,<sup>§</sup> GABRIELA CASABONA, MD,<sup>||</sup> YATES YEN YU CHAO, MD,<sup>¶</sup> JOANA COSTA, MD,<sup>#</sup> JOSEPH EVIATAR, MD, FACS,<sup>\*\*</sup> SABRINA GUILLEN FABI, MD, FAAD, FAACS,<sup>††</sup> MARY LUPO, MD,<sup>‡‡</sup> GERHARD SATTLER, MD,<sup>§§</sup> HEIDI WALDORF, MD,<sup>||¶¶</sup> YANA YUTSKOVSKAYA, MD,<sup>###</sup> AND PAUL LORENC, MD<sup>\*\*\*</sup>

**BACKGROUND** Calcium hydroxylapatite (CaHA) is approved to correct moderate-to-severe wrinkles and folds and soft-tissue volume loss in the face and hands. More recently, subdermal injection using diluted CaHA has been used to improve skin laxity.

**OBJECTIVE** To review evidence for the safe and effective use of diluted CaHA in the face and body and provide best practice recommendations.

**METHODS** A global panel of expert aesthetic physicians convened to develop consensus-based guidelines for treating laxity and superficial wrinkles using diluted (ratio of 1:1) and hyperdiluted ( $\geq 1:2$ ) CaHA.

**RESULTS** Diluted and hyperdiluted CaHA stimulates targeted neocollagenesis in the injection area to improve laxity and skin quality in the mid- and lower face, neck, décolletage, upper arms, abdomen, upper legs, and buttocks. Treatment can be used as an adjunct to volume augmentation or combined with additional modalities for optimal results. Adverse events are related to the injection and include bruising, swelling, mild pain, and induration. In thinner and darker skin, too-superficial injections of less diluted CaHA can lead to more adverse events.

**CONCLUSION** This report provides preliminary guidelines for the novel off-label use of CaHA for biostimulation in the face and body. Further trials will provide additional clarity regarding treatment paradigms for optimal outcomes.

*K. Butterwick is a speaker, research grant, and/or advisor for Allergan, Colorscience, Galderma, Merz, Sinclair Pharmaceuticals, and Thermi Aesthetics. G. Casabona is a speaker and consultant for Allergan and Merz Aesthetics. J. Costa is a speaker and/or advisor and investigator for Bayer and Merz Aesthetics. J. Eviatar is a speaker and/or advisor and investigator for Alastin, Allergan, Galderma, Kythera, Merz, and Revance, and advisor, trainer, and investigator for Thermi Aesthetics. S. Fabi is a speaker and/or advisor and/or investigator for Alastin, Allergan, Almirall, Galderma, Kythera, Merz, and Revance. K. Goldie is a global key opinion leader for Merz Aesthetics. M. Lupo is a speaker, trainer, researcher, and/or consultant for Allergan, Galderma, and Merz Aesthetics. W. Peeters is a speaker and advisor for Bloomedical NV, Integra Life, and Merz Aesthetics. G. Sattler is a speaker and/or advisor for Allergan, Alma, Galderma, and Merz. The remaining authors have indicated no significant interest with commercial supporters.*

\*European Medical Aesthetics Ltd, London, United Kingdom; <sup>†</sup>Plastic and Reconstructive Surgery, AZ KLINA, Brasschaat, Belgium; <sup>‡</sup>Division of Plastic and Reconstructive Surgery, Northwestern Feinberg School of Medicine, Chicago, Illinois; <sup>§</sup>Cosmetic Laser Dermatology, San Diego, California; <sup>||</sup>Scientific Department, Ocean Clinic, Marbella, Spain; <sup>¶</sup>CHAO Institute of Aesthetic Medicine, Taipei, Taiwan; <sup>#</sup>Brasília, Brazil; <sup>\*\*</sup>Oculo-facial Plastic Surgery, State University of New York College of Optometry, New York City, New York; <sup>††</sup>Department of Dermatology, University of California, San Diego, California; <sup>‡‡</sup>Department of Dermatology, Tulane Medical School, New Orleans, Louisiana; <sup>§§</sup>Rosenparkklinik, Darmstadt, Germany; <sup>||¶¶</sup>Waldorf Dermatology Aesthetics, Nanuet, New York; <sup>###</sup>Department of Dermatology, Mount Sinai Hospital, New York, New York; <sup>\*\*\*</sup>Dermatovenerology and Cosmetology Department, Pacific State Medical University of Health, Moscow, Russia; <sup>\*\*\*</sup>Department of Plastic Surgery, Lenox Hill Hospital, New York, New York

© 2018 by the American Society for Dermatologic Surgery, Inc. Published by Wolters Kluwer Health, Inc. All rights reserved.  
ISSN: 1076-0512 • Dermatol Surg 2018;44:S32–S41 • DOI: 10.1097/DSS.0000000000001685

Calcium hydroxylapatite microspheres (CaHA, Radiesse®; Merz Pharmaceuticals GmbH, Frankfurt, Germany) comprise biodegradable particles suspended in an aqueous carboxymethyl cellulose gel carrier.<sup>1</sup> After injection, the particles induce histiocytic and fibroblastic response, acting as a scaffold for new tissue formation and stimulating collagen and elastin formation around the implant for sustained aesthetic improvements.<sup>2–6</sup> CaHA has been used for more than a decade to correct moderate-to-severe wrinkles and folds and soft-tissue volume loss.<sup>4,7–15</sup> Highly viscoelastic, CaHA is well suited for supraperiosteal, subdermal, and deep-dermal placement but may also be injected more superficially for dermal rejuvenation when diluted.<sup>13</sup> Partially diluted CaHA has been shown to be effective and safe for the treatment of atrophic hands.<sup>12,15</sup> Amselem<sup>16</sup> and Cogorno Wasyolkowski<sup>17</sup> published the first reports demonstrating noticeable improvements in skin firmness and appearance after the injection of CaHA diluted with small amounts of lidocaine in the arms, abdomen, and thighs.

The use of filling agents to tighten and improve the appearance of the skin is relatively new. Small aliquots of hyaluronic acid (HA) injected into large areas of the dermis have been shown to induce neocollagenesis and enhance skin turgor and firmness, leading to skin that looks smoother and brighter.<sup>18</sup> Higher dilutions of poly-L-lactic acid, which stimulates production of new collagen through a biostimulatory response, have been used off-label in the chest and other areas of the face and body for skin rejuvenation and revitalization.<sup>19,20</sup>

The development of off-label subdermal injection techniques using diluted or hyperdiluted CaHA to stimulate dermal regeneration without creating a volumizing effect<sup>6,21–23</sup> is a compelling line of investigation that warrants further examination and clarification. To that end, a global panel of aesthetic physicians with experience using this technique reviewed available evidence for the safe and effective use of diluted and hyperdiluted CaHA in the face and body. This report summarizes their findings and recommendations.

## Methodology and Consensus Objectives

In October 2017, a multinational group of 14 experienced leaders in dermatology, plastic surgery, and oculoplastic surgery convened to develop consensus-based guidelines for the off-label treatment of skin laxity and superficial wrinkles using diluted and hyperdiluted CaHA. Diluted CaHA was defined as the original formulation of CaHA reconstituted with lidocaine or saline using ratios of 1:1, whereas hyperdilution refers to reconstitution using ratios of 1:2 or higher (Table 1). A questionnaire distributed to panel members before the meeting served as a basis for the ensuing discussions leading to the consensus statements. Agreement of  $\geq 75\%$  of panel members constituted consensus.

Other guidelines and evidence-based reviews have been published describing the optimal use of undiluted CaHA for volume augmentation.<sup>8,12,24</sup> This report focuses on the novel off-label use of diluted and hyperdiluted CaHA to stimulate targeted neocollagenesis for the purposes of skin tightening and improvements in skin quality, defined as elasticity, firmness, superficial wrinkles, roughness, and overall appearance (Tables 2–4). A review of the literature for CaHA in aesthetic medicine presents strong evidence for neocollagenesis and neoelastogenesis after injection of diluted and hyperdiluted CaHA, as well as improvements in skin quality, particularly in the décolletage (evidence Level C) followed by other areas of the face and body (evidence Level D).<sup>6,21–23</sup> These expert guidelines are meant to provide a broad statement of consensus integrating clinical judgement and best available evidence for colleagues who wish to broaden their portfolio with this new technique. The use of multiple modalities to achieve optimal aesthetic results in the face and body is well documented<sup>25,26</sup>; recommendations for combination therapy are included where relevant.

## Dilution

Undiluted CaHA is a highly viscoelastic product that makes it ideally suited for deep implantation

**TABLE 1. Definitions of Diluted and Hyperdiluted CaHA**

	<i>Dilution Ratio</i>
Diluted CaHA	1:1
Hyperdiluted CaHA	≥1:2
CaHA, calcium hydroxylapatite.	

and volume augmentation.<sup>13,27,28</sup> Dilution with lidocaine and/or saline makes it amenable to more superficial injection and easier to disseminate.<sup>28,29</sup> Lower dilution ratios (<1:1) provide both volume and dermal remodeling, whereas dilution ratios ≥1:1 may be more effective for providing biostimulation. More superficial injection of less diluted CaHA can lead to product visibility, especially in areas of thin or darker skin. In these cases, higher dilutions may be recommended and are noted where appropriate. In Asian skin, panel members have observed that ratios of 1:1 are required to stimulate a response in the neck, décolletage, upper arms, and legs.

Proper dilution involves connecting a LuerLock syringe containing diluent to the original CaHA syringe through a female transfer adaptor. Both syringes should be large enough to easily accommodate the combined filler and diluent. This is particularly important when using higher dilutions and greater total volumes. At least 20 passes between syringes are recommended to ensure product homogeneity. Because the combined mix-

ture tends to separate quickly—especially at higher dilutions—and should be used immediately after reconstitution, the consensus panel recommends dilution by the injector, rather than a nurse practitioner or assistant.

### General Injection Techniques and Considerations

Because the choice and size of needle versus cannula largely depends on injector preference, the panel does not make recommendations for the method of delivery but stresses the aim of treatment: to deliver a thin, uniform coating of diluted or hyperdiluted CaHA to the treatment area. Using lidocaine as the diluent reduces the need for additional anesthesia. Exact injection techniques vary according to the area, amount of product to be injected, and patient need; panel members indicated a preference for fanning and parallel, serial retrograde linear threads in the deep dermal or subdermal plane. Any exceptions to this statement are noted in the appropriate sections below. If needed, vigorous massage of the treated area after injection ensures consistent and even distribution of the product.

### Treatment Intervals and Neocollagenesis

CaHA stimulates dermal remodeling consistent with the 2-step physiologic process of neocollagenesis whereby collagen Type I gradually replaces collagen Type III.<sup>5</sup> This new collagen synthesis may occur as early as 4 weeks after injection and has been observed 3, 6, and 12 months after treatment.<sup>2,3,21,30</sup> Histological examination of skin treated with diluted CaHA using ratios of 1:2, 1:4, and 1:6 demonstrated significant increases in collagen Types I and III 4 months after treatment, with a gradual decline in expression of collagen Type III by 7 to 9 months.<sup>5,6</sup> These results suggest a cycle in which the highest deposition of new collagen and elastin occurs around 4 months after injection, with stability achieved by 9 months.

The panel recommends follow-up 3 to 4 months after initial treatment, unless otherwise indicated; areas treated with higher dilutions may need more frequent assessment to gauge response. One to 3 treatment

**TABLE 2. Recommendations for the Dilution of CaHA**

1	Dilution performed by physician immediately before use
2	Sterile mixing environment
3	3–10 mL counter syringe; larger syringes for higher dilution
4	The higher the dilution, the faster the combined product separates
5	Bring back into original syringe
6	At least 20 passes
CaHA, calcium hydroxylapatite.	

**TABLE 3. General Techniques and Considerations**

- 1 Aim of treatment: deliver a thin, uniform coating of product to entire treatment area
- 2 In the face: entry point perpendicular to major arteries
- 3 Deep dermal or subdermal plane
- 4 Thin, uniform layer of product across the entire treatment area
- 5 Massage vigorously after treatment
- 6 Assess response at 3–4 months; reinject as necessary

sessions are usually required during the first year to achieve optimal aesthetic effect, with maintenance injections every 12 to 18 months thereafter.

### Face

The use of diluted or hyperdiluted CaHA in the mid- and lower face is typically an adjunct to volumizing and sculpting procedures with viscoelastic filling

agents. The panel recommends a “wash,” in which diluted product is placed in the immediate subdermal plane and fanned across the cheeks and jawline. This pan-facial approach tightens the skin without creating bulk. Gently scraping the underside of the dermis supports biostimulation. Choosing entry points perpendicular to major arteries reduces the risk of entry into a vessel. Diluted CaHA using ratios of 1:1 is recommended initially; rarely, hyperdilutions up to ratios of 1:2 may be used for more superficial placement in areas of thin skin or greater laxity. Because diluted CaHA is not used for skin-quality improvements in the forehead or temple, where treatment typically focuses on volume and contour, the panel makes no recommendations for biostimulation in these areas.

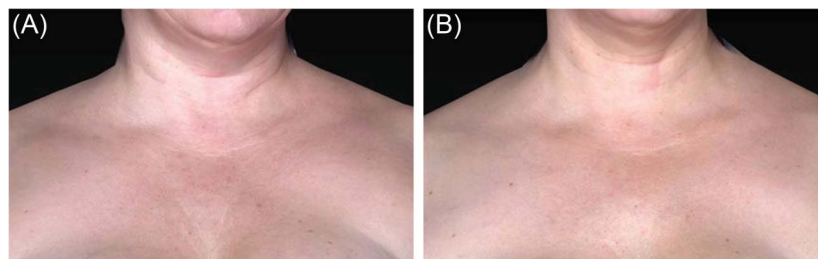
### Neck and Décolletage

Hyperdiluted CaHA effectively tightens skin in the neck and décolletage.<sup>6</sup> Improvements in skin elasticity and pliability and increased dermal thickness translate

**TABLE 4. Recommended Treatment Paradigm for Diluted and Hyperdiluted CaHA**

<i>Indication</i>	<i>Average Volume of Undiluted CaHA</i>	<i>Dilution Ratio</i>	<i>Injection Plane/Technique</i>
Pan-facial rejuvenation	1.5 mL/side	Most commonly 1:1; up to 1:3	Subdermal Retrograde linear fanning
Neck	1.5 mL	1:2–1:4	Immediate subdermal Retrograde linear threads
Décolletage	1.5 mL	1:2–1:4*	Immediate subdermal Retrograde linear threads
Mild laxity of the upper arm	3 mL/arm	1:2*	Immediate subdermal Retrograde linear fanning
Abdomen	1.5 mL/100 cm <sup>2</sup>	1:1	Subdermal Cross-hatching or fanning
Buttocks			
Gluteal sagging; mild dermal irregularities	1.5 mL per side	1:2 and 1:6, layered	Deep dermal Cross-hatching
Mild laxity of the legs	1.5 mL/100 cm <sup>2</sup>	1:2*	Immediate subdermal Horizontal “rasping”
Cellulite	1.5 mL per side	1:1	Subdermal Vectored fanning
Striae	1.5–3 mL per session	1:1	Subcutaneous to superficial dermis Microbolus or retrograde linear thread

\*In select situations and in individuals with thicker skin, dilution ratios of 1:1 may be more appropriate.  
CaHA, calcium hydroxylapatite.



**Figure 1.** Treatment of the décolletage in a 42-year-old woman before (A) and after (B) combination therapy with MFU-V and 1.5 mL CaHA diluted 1:2. Photograph B was taken 12 weeks after the third treatment of CaHA and 180 days after MFU-V. Images provided courtesy of Sabrina Fabi, MD. MFU-V, microfocused ultrasound with visualization. CaHA, calcium hydroxylapatite.

to visible aesthetic improvements and patient satisfaction. In the neck, individuals with only mild laxity and excess skin, and/or all degrees of photodamage will benefit most from treatment. Excess skin will not disappear but will be less visible and tighter due to the stimulation of collagen and elastin. Because the skin of the neck is especially thin and adheres to the underlying platysma, the use of cannulas and dilution ratios of 1:2 to 1:4 are recommended to reduce the risk of too-superficial injections, leading to product visibility and the potential formation of nodules. In select cases, a dilution of 1:1 may be used; this technique is advised only for experienced injectors in patients with a sufficient amount of skin thickness to prevent visibility when the product is placed in the immediate subdermal plane. Asian patients, for whom skin laxity is more of a concern than texture, benefit from 1:1 ratios for ideal improvements. In the décolletage, hyperdiluted CaHA in ratios of 1:2 to 1:3 is recommended for the treatment of mild photodamage and/or skin laxity. Higher dilutions (1:4) are appropriate in individuals with evidence of greater atrophy due to UV-related damage.

Results may be visible after only one treatment. However, it is not always possible to achieve full restoration in one session, especially when using higher dilutions. The panel recommends follow-up at 6 to 9 months to gauge response. A slow and gradual approach is advised for individuals with very thin or photodamaged skin, and multiple interventions are often required for optimal restoration. In the neck, botulinum toxin and low-viscosity HA fillers can soften residual lines and platysmal banding, whereas microfocused ultra-

sound with visualization (MFU-V) is a useful and potentially synergistic adjunctive therapy in the décolletage (Figure 1). Recent guidelines have provided important considerations for the timing and sequence of combined interventions in the face and body.<sup>25,26</sup>

### Upper Arms

Visible signs of aging in the upper arms—loss of tone, elasticity, and undesirable flaccidity—cannot be corrected through exercise alone.<sup>16</sup> Historically, “bat wings” have been treated by brachioplasty, and surgery is still recommended for individuals who have lost a significant amount of weight and have severe skin laxity. Subdermal injection of hyperdiluted CaHA (ratio of 1:2) significantly increases dermal thickness and elasticity<sup>23</sup> and may be an effective alternative to surgery in patients with only mild laxity and excess skin and/or thin, atrophic skin. Treatment improves the appearance of skin crepiness and laxity, although more severe cases may require repeated treatments for optimal results. Best results are observed in patients younger than 50 years. In older individuals, significant effects on skin thickness and elasticity may not be noticeable for 6 months or longer.

To treat the circumferential upper arm, the panel recommends 3 mL of CaHA (2 syringes) diluted 1:2 with lidocaine and saline, for a total of 9 mL of solution to be injected. One syringe (1.5 mL of CaHA plus 3 mL of diluent) is sufficient for the treatment of smaller areas. A dilution ratio of 1:1 may be considered in patients with thicker skin. Product is placed in the immediate subdermal plane and distributed in



small amounts using multiple passes in a semicircular pattern (fanning technique).

## Lower Body

The off-label use of diluted and hyperdiluted CaHA in the abdomen, buttocks, and legs is a relatively new indication. Recommendations provided are based largely on personal experience and require further examination and supporting clinical evidence.

### Abdomen

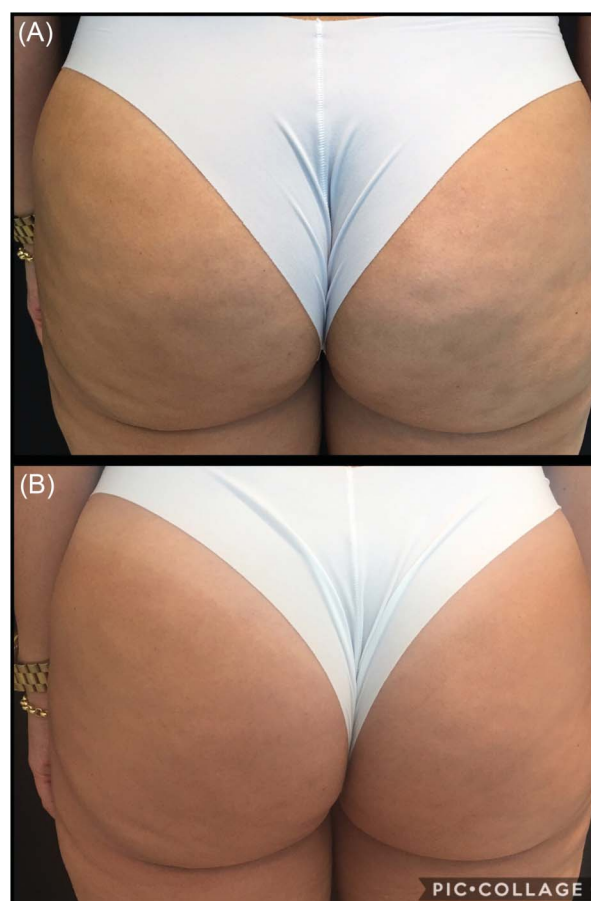
Diluted and hyperdiluted CaHA is indicated in the abdomen for age-related elastosis and postinterventional restoration, increasing dermal thickness and correcting surface and contour irregularities.<sup>23</sup> The tissue of the abdomen is very thick and complicated by the presence of fascial septae that can cause surface indentations. Volume deficits should be corrected first through deep augmentation techniques using autologous fat or other fillers designed to lend strength and support to the underlying tissue. Diluted and hyperdiluted CaHA is layered over this scaffold more superficially using horizontal injection techniques, such as cross-hatching and fanning. The volume of injected material can be calculated using the formulation of 1.5 mL of CaHA for every 100 cm<sup>2</sup> (10×10 cm area) diluted 1:1 (Table 5). This translates to 3 mL of total solution (1.5 mL of CaHA plus 1.5 mL of diluent) for the treatment of the umbilical area, whereas a total of 6 mL may be required to coat a larger area. In cases of atrophy, additional stimulation

and dermal thickening may be enhanced through the use of skin-tightening procedures, such as radio-frequency, MFU-V, or fractional lasers. The panel recommends follow-up 6 to 9 months after treatment.

### Buttocks

Hyperdiluted CaHA in the buttocks targets gluteal sagging and skin contour irregularities, primarily cellulite and striae. Although these indications are treated simultaneously, technique may vary depending on age and the degree of cellulite and/or stretch marks.

Because cellulite and striae can also occur elsewhere in the body, distinct and separate recommendations have



**Figure 2.** To treat mild dermal irregularities in the buttocks, 1.5 mL of CaHA was diluted with 3 mL of lidocaine and saline (1:2 ratio); 2 mL of solution was injected per side in the deep dermis. Skin tightening was accomplished by layering 1.5 mL of CaHA diluted with 9 mL of lidocaine and saline (1:5 ratio) using a cross-hatching technique; 6 mL of solution was injected per side. The figure demonstrates before (A) and after (B) 3 sessions using 2 syringes of CaHA. CaHA, calcium hydroxylapatite. Images provided courtesy of Joana Costa, MD.

**TABLE 5. Volume Calculations for Diluted and Hyperdiluted CaHA in the Arms, Legs, and Abdomen**

*Formulation: 1.5 mL/100 cm<sup>2</sup> (Area of 10 × 10 cm)*

Undiluted CaHA	Dilution Ratio	Total Volume/100 cm <sup>2</sup> Injected
1.5 mL (one syringe)	1:1	3 mL
	1:2	4.5 mL
	1:3	6 mL
	1:4	7.5 mL
	1:5	9 mL

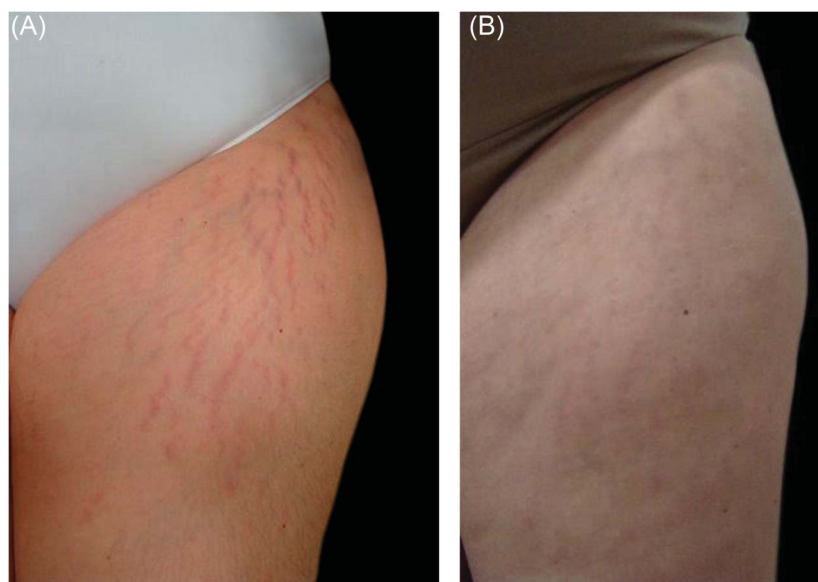
CaHA, calcium hydroxylapatite.

been made for all indications. For younger individuals with gluteal sagging and only mild surface irregularities, the buttocks can be shaped (lifting and smoothing) using layered dilutions of product (Figure 2). CaHA hyperdiluted 1:2 to 1:6 (depending on the thickness of the dermis) is injected subdermally in vertical lines around the contour of the buttocks, especially in the upper and lateral region. A horizontal cross-hatching technique is used for cellulite and skin irregularities in the lower region. If the skin of the buttocks is thin, using higher dilutions will lessen the risk of product agglomeration or visibility. Three treatment sessions every 3 to 4 months may be required for optimal outcomes. Microfocused ultrasound can be used before treatment with CaHA to maximize the lift potential,<sup>26</sup> although individuals with a higher body mass index (BMI) may not experience a satisfying aesthetic improvement from skin tightening alone.<sup>31</sup>

### Cellulite

Cellulite involves a transformation and alteration of subcutaneous tissues and is not merely an accumu-

lation of fat.<sup>21</sup> Changes in the fibrous structure of the skin and increased skin laxity contribute to the worsening of cellulite, particularly in women older than 35 years.<sup>32</sup> Increasing the strength and elasticity of both the dermis and superficial fascia through neocollagenesis and remodeling are important aims when treating skin laxity to improve the appearance of cellulite.<sup>33</sup> Panel members recommend CaHA diluted 1:1 with lidocaine injected subdermally using a vectored-fanning approach. Because the fascia deepens over time and may lie as far as 6 mm below the epidermis in older individuals or those with a higher BMI, multiple modalities are sometimes required to provide adequate stimulation at all appropriate treatment depths. There is considerable rationale for combining CaHA with MFU-V because both stimulate remodeling of the dermis and collagenous structures in the superficial fascia.<sup>21,34</sup> The combination of diluted CaHA injected immediately after the use of MFU-V has been shown to significantly improve the appearance of cellulite, including the number and depth of depressions, skin surface appearance, and degree of skin laxity.<sup>21</sup>



**Figure 3.** Pre- and post-treatment images of a 32-year-old subject who developed acute deep striae rubrae in the anterior thigh after pregnancy. Baseline appearance of striae (A) is much improved after treatment with 1:1 diluted CaHA followed by 3 sessions of topical ascorbic acid and microneedling (B), one month after the last treatment session. CaHA, calcium hydroxylapatite. Images reproduced with permission from Casabona G, Marchese P. Calcium hydroxylapatite combined with microneedling and ascorbic acid is effective for treating stretch marks. *Plast Reconstr Surg Glob Open* 2017;5:e1474. <https://journals.lww.com/prsgo>. Published by Wolters Kluwer Health, Inc. on behalf of the American Society of Plastic Surgeons. Promotional and commercial use of the material in print, digital or mobile device format is prohibited without the permission from the publisher Wolters Kluwer. Please contact [permissions@lww.com](mailto:permissions@lww.com) for further information.

## Stretch Marks

Striae distensae is a permanent type of dermal scarring that is initially red and becomes white and more atrophic.<sup>35</sup> Stretch marks are characterized by densely packed areas of thin, horizontally arranged bundles of collagen running parallel to the skin surface, and a reduction in the number of fibrillin and elastin fibers in the papillary dermis.<sup>36</sup> CaHA in its diluted and hyperdiluted form has been shown to increase the quantity and quality of dermal collagen and elastin fibers in atrophic striae (Figure 3).<sup>22</sup>

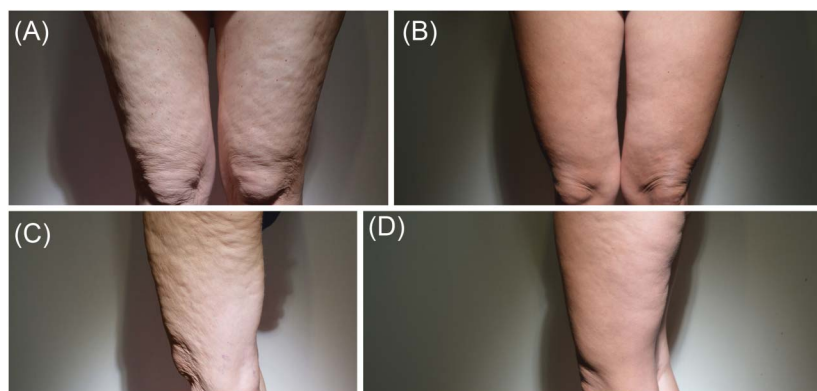
Striae lie just below the reticular dermis and represent a loss in dermal content (i.e., a gap in the dermis). Treatment with diluted CaHA aims to fill that gap using a combined deep subdermal and intradermal microbolus technique (“string of pearls”), depositing 0.05 mL at each point along the center of the stria, or injecting one or 2 strands of filler in each stria using a retrograde linear threading technique (0.5 mL per strand). More superficial injection of diluted product can result in greater product visibility beneath the skin, often associated with a yellowish discoloration; this addition of color may lend white striae a more natural appearance, enhancing the overall aesthetic effect. The precise amount to inject is difficult to quantify and depends more on depth than length of each stria. The panel recommends injecting product until the depression cannot be felt with a finger. Smoothing the injected material after injection will ensure the “gap” is closed.

## Legs

Treatment of the leg with diluted and hyperdiluted CaHA focuses on improving skin quality on the anterior and posterior surfaces of the thigh and the area just above the knee by reducing skin flaccidity and increasing skin thickness and density (Figure 4).<sup>17</sup> The ideal patient is one with mild skin irregularities and limited skin laxity without excess fat. As with other areas of the body, volume can be calculated using a formulation of 1.5 mL of CaHA for every 100 cm<sup>2</sup> diluted 1:2 with lidocaine and saline. A rasping technique, in which stiff cannulas inserted subdermally are used to scrape the dermis, delivers diluted product horizontally across wider areas of skin. Even with the use of cannulas, bruising can be significant due to the presence of varicose veins in this area that may be punctured. Patients with more severe laxity or thicker skin may require dilutions of 1:1 and combination therapy using other skin-tightening devices to achieve optimal results. Postinjection vigorous massage is critical to ensure proper distribution of the product.

## Adverse Events

CaHA has been used for more than a decade for facial rejuvenation and HIV-associated lipoatrophy with few complications.<sup>37</sup> In large, long-term studies performed with CaHA, adverse events were minor and mostly restricted to injection-related side effects such as ecchymosis, erythema, inflammation, and edema.<sup>4,9,10,38</sup> Noninflammatory nodule formation—indicating aggregation of material—was primarily



**Figure 4.** Before (A and C) and 6 months after (B and D) first treatment with 6 mL of CaHA diluted 1:1 per leg in a 35-year-old woman who received 2 treatments 3 months apart. CaHA, calcium hydroxylapatite. Images provided courtesy of Wouter Peeters, MD.



associated with use of CaHA in the lips, for which it is no longer indicated, or too-superficial placement of product in the nasolabial folds.<sup>4,38</sup> No long-term or delayed-onset events, granulomas, or infections have been reported.<sup>39</sup> In recent studies using diluted or hyperdiluted CaHA, all adverse events were related to the injection itself and included bruising, swelling, mild pain, and induration.<sup>6,16,21</sup> Two subjects with Fitzpatrick skin Type III developed postinflammatory hyperpigmentation.<sup>22</sup> No severe or persistent complications have been reported to date.

The rarest but most severe complication of all injectable implants in the face is vascular compromise, in which inadvertent injection of product into a blood vessel results in occlusion and painful ischemia with subsequent necrosis.<sup>40,41</sup> It is site-dependent and occurs most frequently in the glabella and nasolabial fold.<sup>42</sup> Rarely, intravascular injections have led to occlusion of the ophthalmic and central retinal artery and blindness.<sup>43</sup> To date, no reports of vascular occlusion after the use of diluted and hyperdiluted CaHA have been reported.

## Conclusion

CaHA has been used safely and effectively for over a decade to correct moderate-to-severe wrinkles and folds and soft-tissue volume loss. When injected more superficially in the subdermal plane in its diluted and hyperdiluted form in the mid- and lower face, neck and décolletage, upper arms, buttocks, thighs, and abdomen, CaHA appears to promote dermal remodeling through stimulation of collagen and elastin for a skin-tightening effect and to improve superficial wrinkles, elasticity, and skin thickness. Because the evidence in the literature to support this practice is limited at present, this report provides preliminary guidelines for the novel, off-label use of CaHA as a biostimulatory agent in the face and body with the expectation that future rigorous clinical trials will provide further evidence for optimal outcomes.

## References

- Berlin A, Cohen JL, Goldberg DJ. Calcium hydroxylapatite for facial rejuvenation. *Semin Cutan Med Surg* 2006;25:132–7.
- Marmur ES, Phelps R, Goldberg DJ. Clinical, histologic and electron microscopic findings after injection of a calcium hydroxylapatite filler. *J Cosmet Laser Ther* 2004;6:223–6.
- Berlin AL, Hussain M, Goldberg DJ. Calcium hydroxylapatite filler for facial rejuvenation: a histologic and immunohistochemical analysis. *Dermatol Surg* 2008;34(Suppl 1):S64–7.
- Tzikas TL. A 52-month summary of results using calcium hydroxylapatite for facial soft tissue augmentation. *Dermatol Surg* 2008;34(Suppl 1):S9–15.
- Yutskovskaya Y, Kogan E, Leshunov E. A randomized, split-face, histomorphologic study comparing a volumetric calcium hydroxylapatite and a hyaluronic acid-based dermal filler. *J Drugs Dermatol* 2014;13:1047–52.
- Yutskovskaya YA, Kogan EA. Improved neocollagenesis and skin mechanical properties after injection of diluted calcium hydroxylapatite in the neck and décolletage: A pilot study. *J Drugs Dermatol* 2017;16:68–74.
- Silvers SL, Eviatar JA, Echavez MI, Pappas AL. Prospective, open-label, 18-month trial of calcium hydroxylapatite (Radiesse) for facial soft-tissue augmentation in patients with human immunodeficiency virus-associated lipoatrophy: one-year durability. *Plast Reconstr Surg* 2006;118(3 Suppl):34S–45S.
- Graivier MH, Bass LS, Busso M, Jasin ME, et al. Calcium hydroxylapatite (Radiesse) for correction of the mid- and lower face: consensus recommendations. *Plast Reconstr Surg* 2007;120(6 Suppl):55S–66S.
- Smith S, Busso M, McClaren M, Bass LS. A randomized, bilateral, prospective comparison of calcium hydroxylapatite microspheres versus human-based collagen for the correction of nasolabial folds. *Dermatol Surg* 2007;33(Suppl 2):S112–21.
- Bass LS, Smith S, Busso M, McClaren M. Calcium hydroxylapatite (Radiesse) for treatment of nasolabial folds: long-term safety and efficacy results. *Aesthet Surg J* 2010;30:235–8.
- Chao YY, Chiu HH, Howell DJ. A novel injection technique for horizontal neck lines correction using calcium hydroxylapatite. *Dermatol Surg* 2011;37:1542–5.
- Emer J, Sundaram H. Aesthetic applications of calcium hydroxylapatite volumizing filler: an evidence-based review and discussion of current concepts: (part 1 of 2). *J Drugs Dermatol* 2013;12:1345–54.
- Loghem JV, Yutskovskaya YA, Werschler W. Calcium hydroxylapatite over a decade of experience. *J Clin Aesthet Dermatol* 2015;8:38–49.
- Lorenc ZP, Lee JC. Composite volumization of the aging face: supra-periosteal space as the foundation for optimal facial rejuvenation. *J Drugs Dermatol* 2016;15:1136–41.
- Goldman MP, Moradi A, Gold MH, Friedmann DP, et al. Calcium hydroxylapatite dermal filler for treatment of dorsal hand volume loss: results from a 12-month, multicenter, randomized, blinded trial. *Dermatol Surg* 2018;44:75–83.
- Amselem M. Radiesse: a novel rejuvenation treatment for the upper arms. *Clin Cosmet Investig Dermatol* 2015;9:9–14.
- Cogorno Wasylkowski V. Body vectoring technique with Radiesse for tightening of the abdomen, thighs, and brachial zone. *Clin Cosmet Investig Dermatol* 2015;8:267–73.
- Streker M, Reuther T, Krueger N, Kerscher M. Stabilized hyaluronic acid-based gel of non-animal origin for skin rejuvenation: face, hand, and décolletage. *J Drugs Dermatol* 2013;12:990–4.
- Alessio R, Rzany B, Eve L, Grangier Y, et al. European expert recommendations on the use of injectable poly-L-lactic acid for facial rejuvenation. *J Drugs Dermatol* 2014;13:1057–66.

20. Lorenc ZP, Fitzgerald R, Vlegaar D, Butterwick KJ, et al. Consensus recommendations on the use of injectable poly-L-lactic acid for facial and nonfacial volumization. *J Drugs Dermatol* 2014;13(4 Suppl):s44–51.
21. Casabona G, Pereira G. Microfocused ultrasound with visualization and calcium hydroxylapatite for improving skin laxity and cellulite appearance. *Plast Reconstr Surg Glob Open* 2017;5:e1388.
22. Casabona G, Marchese P. Calcium hydroxylapatite combined with microneedling and ascorbic acid is effective for treating stretch marks. *Plast Reconstr Surg Glob Open* 2017;5:e1474.
23. Lapatina NG, Pavlenko T. Diluted calcium hydroxylapatite for skin tightening of the upper arms and abdomen. *J Drugs Dermatol* 2017;16:900–6.
24. Dallara JM, Baspeyras M, Bui P, Cartier H, et al. Calcium hydroxylapatite for jawline rejuvenation: consensus recommendations. *J Cosmet Dermatol* 2014;13:3–14.
25. Carruthers J, Burgess C, Day D, Fabi SG, et al. Consensus recommendations for combined aesthetic interventions in the face with botulinum toxin, fillers, and energy-based devices. *Dermatol Surg* 2016;42:586–97.
26. Fabi SG, Burgess C, Carruthers A, Carruthers J, et al. Consensus recommendations for combined aesthetic interventions using botulinum toxin, fillers, and microfocused ultrasound in the neck, décolletage, hands, and other areas of the body. *Dermatol Surg* 2016;42:1199–208.
27. Sundaram H, Voigts B, Beer K, Meland M. Comparison of the rheological properties of viscosity and elasticity in two categories of soft tissue fillers: calcium hydroxylapatite and hyaluronic acid. *Dermatol Surg* 2010;36:1859–65.
28. Meland M, Groppi C, Lorenc ZP. Rheological properties of calcium hydroxylapatite with integral lidocaine. *J Drugs Dermatol* 2016;15:1107–10.
29. Busso M, Voigts R. An investigation of changes in physical properties of injectable calcium hydroxylapatite in a Carrier gel when mixed with lidocaine and with lidocaine/epinephrine. *Dermatol Surg* 2008;34(Suppl 1):S16–23.
30. Coleman KM, Voigts R, DeVore DP, Termin P, et al. Neocollagenesis after injection of calcium hydroxylapatite composition in a canine model. *Dermatol Surg* 2008;34(Suppl 1):S53–5.
31. Sasaki G, Tevez A. Microfocused ultrasound for nonablative skin and subdermal tightening to the periorbitum and body sites: preliminary report on eighty-two patients. *J Cosmet Dermatol Sci Appl* 2012;2:109–16.
32. Lorencini M, Camozzato F, Hessel D. Skin aging and cellulite in women. In: Farage MA, Miller KW, Maibach HI, editors. *Textbook of Aging Skin*. Berlin, Germany: Springer; 2016; pp. 1–9.
33. Hessel D, Hessel C. The role of skin tightening in improving cellulite. *Dermatol Surg* 2014;40:S180–3.
34. Casabona G, Michalany N. Microfocused ultrasound with visualization and fillers for increased neocollagenesis: clinical and histological evaluation. *Dermatol Surg* 2014;40(Suppl 12):S194–8.
35. Elsaie ML, Baumann LS, Elsaie LT. Striae distensae (stretch marks) and different modalities of therapy: an update. *Dermatol Surg* 2009;35:563–73.
36. Singh G, Kumar LP. Striae distensae. *Indian J Dermatol Venereol Leprol* 2005;71:370–2.
37. Kadouch JA. Calcium hydroxylapatite: a review on safety and complications. *J Cosmet Dermatol* 2017;16:152–61.
38. Sadick NS, Katz BE, Roy D. A multicenter, 47-month study of safety and efficacy of calcium hydroxylapatite for soft tissue augmentation of nasolabial folds and other areas of the face. *Dermatol Surg* 2007;33(Suppl 2):S122–6.
39. Pavicic T. Calcium hydroxylapatite filler: an overview of safety and tolerability. *J Drugs Dermatol* 2013;12:996–1002.
40. Darling MD, Peterson JD, Fabi SG. Impending necrosis following injection of hyaluronic acid and calcium hydroxylapatite fillers: report of 2 cases and review of management, including hyperbaric oxygen therapy. *Dermatol Surg* 2014;40:1049–52.
41. Eviatar J, Lo C, Kirsztrot J. Radiesse: advanced techniques and applications for a unique and versatile implant. *Plast Reconstr Surg* 2015;136(5 Suppl):164S–170S.
42. Beleznyay K, Humphrey S, Carruthers JD, Carruthers A. Vascular compromise from soft tissue augmentation: experience with 12 cases and recommendations for optimal outcomes. *J Clin Aesthet Dermatol* 2014;7:37–43.
43. Breithaupt A, Fitzgerald R. Collagen stimulators: poly-L-lactic acid and calcium hydroxylapatite. *Facial Plast Surg Clin North Am* 2015;23:459–69.

---

Address correspondence and reprint requests to: Kate Goldie, European Medical Aesthetics Ltd., MBChB, 77 Harley Street, London W1G8QN, United Kingdom, or e-mail: kate@medicsdirect.com